
*Appendicitis is easily missed or
wrongly diagnosed - imaging is
needed*

Ms Abeeda Butt

-
- Acute appendicitis is the most common cause of acute abdomen requiring surgical intervention
 - Unfortunately, 20-33% of the patients suspected of having acute appendicitis present with atypical findings.
 - Diagnosis of atypical appendicitis is a difficult task and remains a clinical challenge that may test the diagnostic skills of even the most experienced surgeons.
-

Diagnostic difficulties

Precaution appendectomy or misdiagnosis of presumed appendicitis is an adverse outcome that leads to unnecessary surgery, serious interruption of patient's daily activities and considerable waste of hospital resources, in addition to the recognized postoperative complications. On the other hand, delay in diagnosis may increase the morbidity and cost.

Statistics reported that 1 of 5 cases of appendicitis is misdiagnosed; however, a normal appendix is found in 15-35% of patients who have emergency appendectomy .

normal

Bisard D, Rosenfield JC, Estrada F, Reed JF: Institutioning a clinical guideline practice to decrease the rate of appendectomies. Am Surg; 2003; 69:796-8 -

Despite technologic advances, the diagnosis of appendicitis is still based primarily on the patient's history and the physical examination. It has been estimated that the accuracy of the clinical diagnosis of acute appendicitis is lying between 76% and 92%, with values correlating with the surgeon's experience.

Over the years various clinical scoring systems have been used, and, although their clinical benefits have varied. The greatest beneficiaries may be junior staff, whose diagnostic accuracy increases from 58% to 71%.

High risk group patients

- Ovulating women
 - Pregnant females
 - **Mortality rate if missed = 2 % for mother, up to 35 % for fetus**
 - Paediatrics
 - Up to 50 % initially misdiagnosed**
 - **< 2 yrs. : perforation rate approaches 100 %**
 - **3 to 5 yrs. = 71 %**
 - **6 to 10 yrs. = 40 %**
 - Elderly
 - **Perforation rate = 46 to 83 %**
 - Immunocompromised patients
-

Imaging modalities

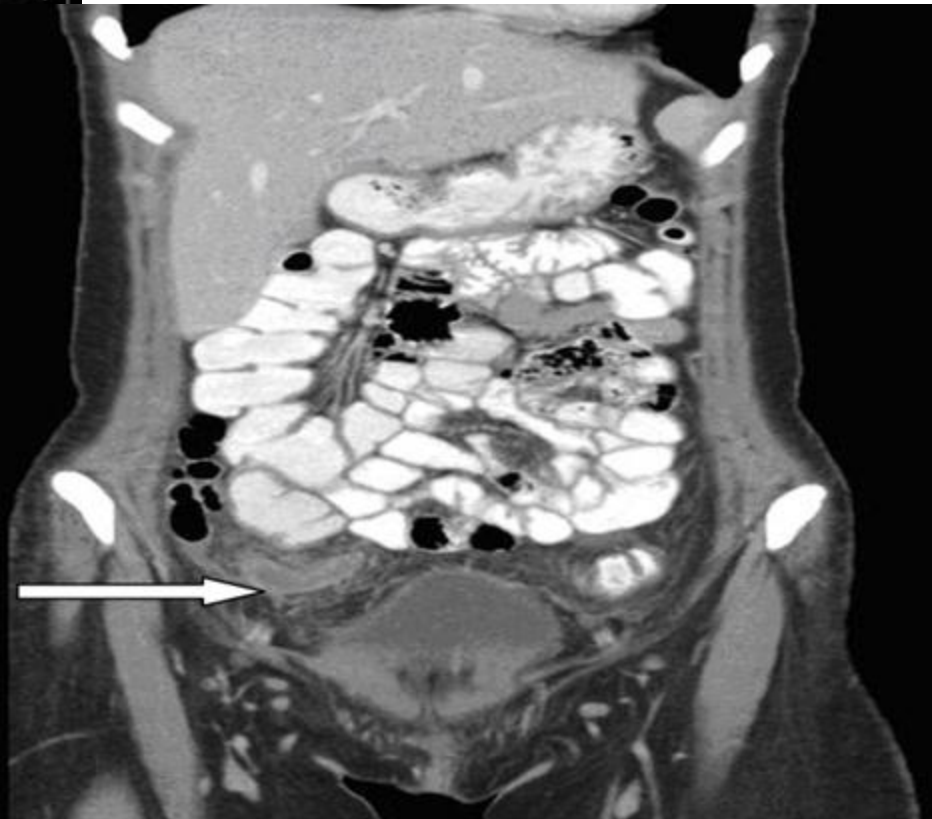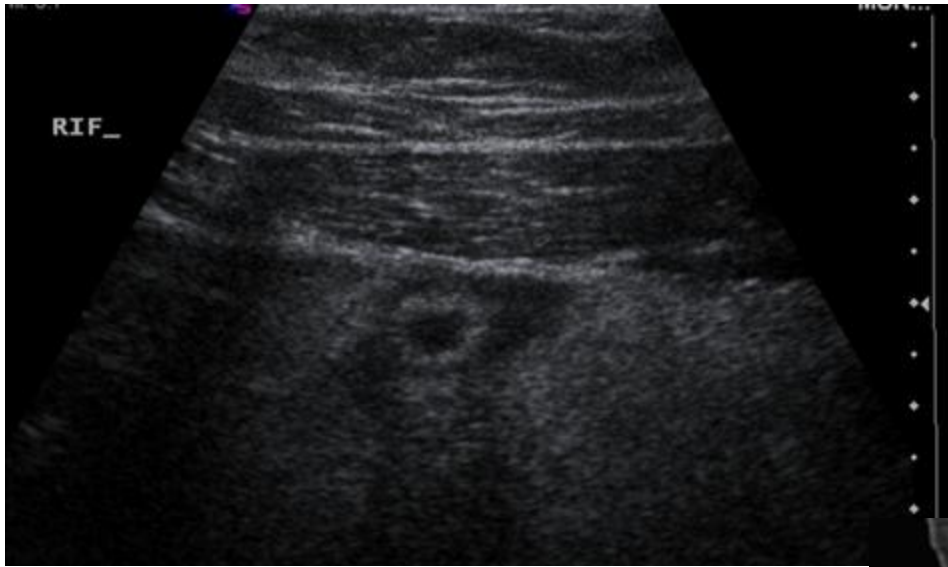- ***Ultrasonography***

Graded compression Sonography is relatively inexpensive, rapid, non-invasive, and requires no patient preparation or contrast material administration.

Unfortunately, it is operator-dependent and requires a high level of skill and expertise.

It is also a dynamic investigation, and photographs of sonographic images cannot be reliably re-evaluated.

The overall sensitivity, specificity and accuracy of ultrasonography in the diagnosis of acute appendicitis were 78%, 92% and 87%.

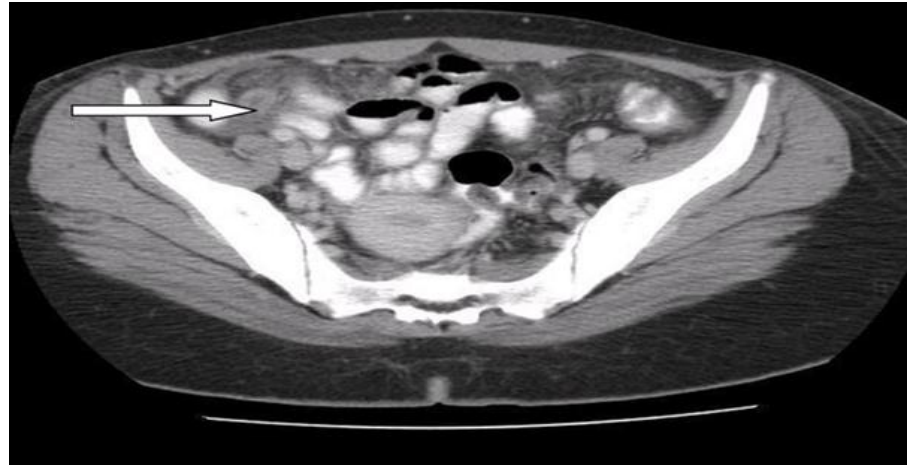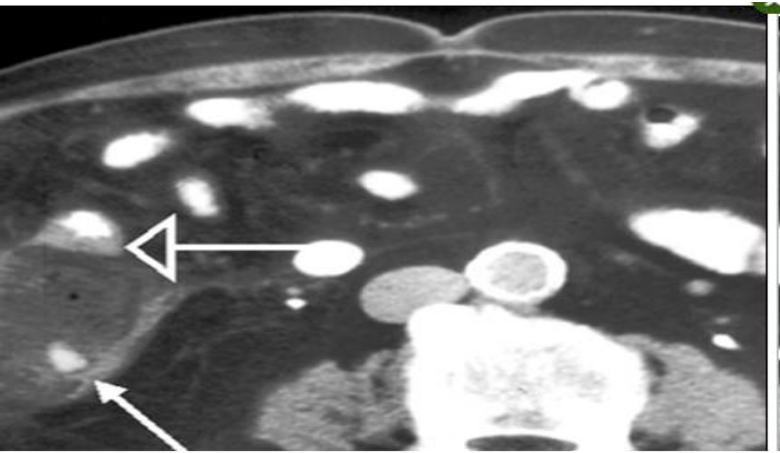


CT scan

- CT is more accurate in the diagnosis of acute appendicitis since it is less operator dependent.
- Although in most cases the diagnosis of acute appendicitis is usually clear, there is still a significant negative appendicectomy rate.
- Multidetector-row CT (MDCT) currently has an important role in the diagnosis of acute appendicitis and its severity. Some authors suggest that they can diagnose acute appendicitis with an accuracy of 99%.⁽⁷⁾

Therefore, some authorities now recommend CT for all patients with suspected acute appendicitis or for those with equivocal acute appendicitis.

- The typical CT finding of an inflamed appendix is a thickened wall and a non-filling appendix associated with periappendicular inflammatory fluid , periappendiceal fat stranding.



- CT is a readily available, easy to perform, well-established technique in the study of acute abdominal pain and has shown high sensitivity 90-100%, and specificity 91-99%, accuracies of 94-98%, positive predictive values of 92-98%, and negative predictive values of 95-100% for diagnosing acute appendicitis .

Magnetic Resonance Imaging

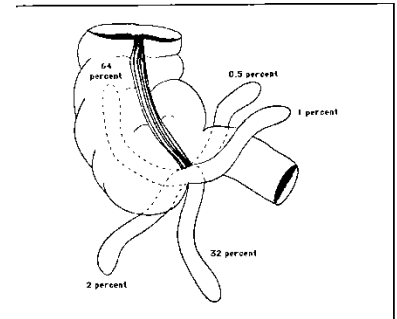
- At this time, there are few studies evaluating the value of magnetic resonance imaging (MRI) for acute appendicitis. MRI is desirable due to its lack of ionizing radiation; however, it is limited due to its higher cost, slower acquisition time, and lesser clinical availability. Several small, retrospective studies cite sensitivity of 97% to 100% and specificity of 92% to 94%. It is anticipated that as MRI becomes more clinically available, the value of MRI for right lower quadrant pain will be further elucidated.
-

Diagnostic laparoscopy

Several authors have advocated the use of laparoscopy as a diagnostic modality in the evaluation of a patient suspected of having acute appendicitis.

- ❑ an invasive procedure requiring general anesthesia and having a risk similar to appendectomy. So, it is not preferred as a diagnostic tool.
 - ❑ Diagnostic laparoscopy may be helpful in equivocal cases or in women of childbearing age but it should not be advocated as a routine diagnostic procedure to replace the classical pre-operative work-up usually performed for clinically suspected appendicitis, because it has its own morbidity
 - ❑ Kraemer et al. reviewed the literature for the years 1978 to 1998 to analyze the negative appendectomy rates, complication rates, the accuracy of laparoscopic appendix assessment, and the incidence of false negative diagnosis of appendicitis. He concluded that, contrary to general opinion, there is no substantial evidence to support the assumption that the macroscopic diagnosis of appendicitis is unreliable. The role of diagnostic laparoscopy in suspected appendicitis should be reconsidered.
-

ADVANTAGES of CT scan



Vermiform appendix Diagram showing the approximate prevalence of various locations of the appendix. Like the hands of a clock, the appendix may be long or short, and it may occupy any position consistent with its length. Reproduced with permission from Grant's Atlas of Anatomy, 7th ed, Williams & Wilkins Company, Baltimore, MD. Copyright 1978 Williams & Wilkins.

- ❑ Painless, non invasive
- ❑ Position of appendix & appropriate incision /technique (CT may also be helpful in the preoperative evaluation of patients undergoing laparoscopic appendectomy)
- ❑ Potential to reveal alternate diagnosis.
- ❑ Morbidity mortality rate of laparoscopy(Laparoscopy is, however, a costly technique associated with a risk of complications such as bladder and bowel injuries, and wound infections and the possibility that a final diagnosis may still not be made ([Moberg 1998](#)).
- ❑ One study with laparoscopic examination reported that histopathological examination of the appendix showed no acute inflammation of the appendix in 24.9% of operated cases ([Koch 2002](#)).
- ❑ Cost effective as reduce length of stay n bed charges. (3000 Euro for diag lap in CUH)
- One study showed negative laparotomy rates of 4 % in men, 8 % in ovulating women with CT (typical is 20 % and 45 % respectively), but no change in perforation rate
- ❑ Another study showed increase in CT use led to earlier diagnosis, less severe pathologic findings, and decreased length of stay.

❑ Appendicitis is easily missed or wrongly diagnosed - imaging is needed

❑ BMJ 17 October 2011

DISADVANTAGES

- COST! 180 Euro
 - Radiation exposure.
 - It is predicted that 2 percent of future cancers will be caused by radiation from computed tomography (CT) exposure.
 - The potential for anaphylactoid reaction if intravenous (IV) contrast is used,
 - lengthy preparation time if oral contrast is used, and
 - patient discomfort if rectal contrast is used
-

Literature review

Role of focused appendiceal computed tomography in clinically equivocal acute appendicitis

Methods:

The study was conducted in Aga Khan University Hospital, Karachi, over a period of one year. Sixty-three patients with clinically equivocal acute appendicitis underwent thin-section non-enhanced helical CT. Axial scans were obtained in a single breath hold from L2 vertebral level to the pubic symphysis with 5-mm collimation and a pitch of 1.5. All scans were obtained without oral, intravenous, or rectal contrast material.

Results: There were 21 true-positive diagnoses, 38 true-negative diagnoses, no false-positive diagnoses, and 2 false-negative diagnoses, which yielded a sensitivity of 91% and a specificity of 100%.

Conclusion: Non-enhanced FACT is a highly accurate problem solving technique in clinically equivocal cases of acute appendicitis

(JPMA 56:200;2006).

Diagnostic Accuracy of Focused Appendiceal CT in Clinically Equivocal Cases of Acute Appendicitis

- **MATERIALS AND METHODS:** One hundred patients (age range, 14–81 years; mean age, 30.6 years) with equivocal symptoms and signs of acute appendicitis were included in this prospective study. Patients were given 30 mL of diatrizoate meglumine and diatrizoate sodium and 60 mL of sorbitol mixed in 1 L of water orally over 1 hour. CT was performed 1.5 hours after the commencement of oral contrast material administration
- **RESULTS:** Of 100 cases, 30 were positive at CT and 70 were negative. There were 28 true-positive cases; two false-positive cases, one cecal diverticulitis and one pelvic peritonitis with periappendicitis; and two false-negative cases, one perforated appendix and one mucosal and submucosal inflammation of the appendix but no transmural inflammation. Sensitivity was 93%, specificity was 97%, and accuracy was 96%.
- **CONCLUSION:** Focused appendiceal CT in which oral contrast material is used alone yields high levels of accuracy in clinically equivocal cases of acute appendicitis.

The role of computed tomography in clinically-suspected but equivocal acute appendicitis.

■ **METHODS:**

The records of 206 consecutive patients who had CT of the abdomen and pelvis for equivocal signs and symptoms of acute appendicitis were reviewed. The criteria used to diagnose acute appendicitis were: (a) a thickened appendix of more than 7 mm or (b) inflammatory changes in the periappendiceal fat. The CT findings were correlated with the histological diagnosis at appendectomy. If the CT findings were negative for acute appendicitis and surgery not performed, the results were correlated with other corroborating diagnostic investigations or clinical follow-up.

■ **RESULTS:**

A total of 206 patients were scanned, of which 39 were excluded due to lack of any follow-up. Of the final 167 that were studied, there were 36 true positives, 127 true negatives, 4 false negatives and no false positives, resulting in a sensitivity of 93.9 percent, specificity of 100 percent and accuracy of 98.5 percent.

■ **CONCLUSION:**

Ct is a safe, reliable and accurate modality in the diagnosis of acute appendicitis in patients with equivocal presentation.

Acute abdominal pain: diagnostic impact of immediate CT scanning.

- **METHODS:**

A retrospective review of 2,222 patients with acute abdominal pain who underwent contrast enhanced CT scanning within 24 h after admission. The diagnoses obtained were compared with the final diagnoses after 1 month.

- **RESULTS:**

In 28 cases a conclusive CT examination could not be carried out. The suggested diagnoses were correct in 2,151 cases (96.8%). In 16 cases (0.7%) an incorrect diagnosis was reported, leading to 7 unnecessary laparotomies. False negative reports were obtained in 27 cases (1.2%). After CT examination 500 patients could be discharged immediately.

- **CONCLUSIONS:**

Contrast-enhanced CT scanning results in superior diagnostic precision in patients with acute abdominal pain. The present work supports the strategy to include this examination early in the routine diagnostic process.

Guideline on diagnosis and treatment of acute appendicitis: imaging prior to appendectomy is recommended

Every year, over 2500 unnecessary appendectomies are carried out in the Netherlands. At the initiative of the Dutch College of Surgeons, the evidence-based guideline on the diagnosis and treatment of acute appendicitis was developed.

This guideline recommends that appendectomy should not be carried out without prior imaging. Ultrasonography is the recommended imaging technique in patients with suspected appendicitis. After negative or inconclusive ultrasonography, a CT scan can be carried out. Appendectomy is the standard treatment for acute appendicitis; this can be done either by open or laparoscopic surgery.

ACR Appropriateness Criteria® right lower quadrant pain — suspected appendicitis

- In a meta-analysis of six prospective studies through February 2006 of the accuracy of CT and ultrasound (US) in adolescents and adults, CT demonstrated superior sensitivity (91%, 95% confidence interval [CI], 84% to 95%) and specificity (90%; 95% CI, 85% to 94%) versus US (sensitivity 78%; 95% CI, 67% to 86%; specificity 83%, 95% CI, 76% to 88%). The results of investigations of CT showed consistent results across all studies and institutions, while US investigations demonstrated heterogeneity. Small studies suggest that thinner slices and multiplanar reformats increase confidence in identifying the appendix.
 - Another question is whether to use intravenous (IV) contrast in the CT evaluation of appendicitis. High accuracy has been reported for both techniques, but the few direct comparisons available in the literature suggest higher accuracy when IV contrast is used
-

-
- The routine use of CT to evaluate for appendicitis has also been shown to decrease overall costs by \$447 to \$1,412 per patient, and has been shown to decrease the negative appendectomy rate from 42.9% to 7.1% among women aged 18 to 45 years. Clinical accuracy in diagnosing right lower quadrant pain in women of child-bearing age tends to be less accurate compared with adult men, thereby suggesting a lower threshold for imaging in this population.
-

MDCT for suspected appendicitis in the elderly: diagnostic performance and patient outcome

- Elderly adults are at increased risk for complications related to both delayed diagnosis of appendicitis and to unnecessary appendectomy.
- The diagnostic performance of computed tomography (CT) in a consecutive elderly cohort with clinically suspected appendicitis. CT findings and clinical outcomes were analyzed for 262 consecutive adult patients age 65 and older referred for clinically suspected appendicitis at a single medical center between January 2000 and December 2009.
- The overall prevalence of proven acute appendicitis in this elderly cohort with clinically suspected appendicitis was 16.8%. CT sensitivity, specificity, PPV, and NPV for acute appendicitis were 100%, 99.1%, 95.7%, and 100.0%, respectively. The negative appendectomy rate was 2.3% (1/43). There were no false-negative and two false-positive CT interpretations.

-
- Low-dose CT is nearly equivalent to the standard-dose scan for diagnosing appendicitis, and it's accurate enough to serve as a first-line diagnostic modality while delivering less than one-fourth the radiation dose of full-strength CT,
 - study published in the April 26 April 2012 -- *New England Journal of Medicine*.

 - After injection of iodinated contrast, images were acquired in CT scanners with 16, 64, or 256 detector rows for an effective radiation dose of 2 mSv in the low-dose group and 8 mSv in the standard-dose group, and it was adjusted automatically for the patient's body size.

 - In two groups comprising more than 900 patients who presented to the emergency department with suspected appendicitis, the negative appendectomy rate in the low-dose CT group was statistically equivalent to that of the standard-dose group. So despite a few shortcomings -- such as higher odds of needing a second imaging exam to confirm the findings -- the low-dose scan is robust enough to serve as the first-line modality, the authors concluded.
 - *NEJM*:2012. Low-dose CT good enough to diagnose appendicitis
-

-
- The removal of a normal appendix has substantial complications and costs.
 - Bijnen et al found that in patients who underwent a negative appendectomy for suspected appendicitis, complications occurred in 6% patients, re-operation was performed in 2% of patients, and the mean extra hospital costs of a negative appendectomy were EUR 2712.
 - Another study, performed in the United States, estimated that 261,134 patients underwent non incidental appendectomies in 1997, of which 15.3% were negative for appendicitis. The authors reported that women had a higher rate of removal of a normal appendix. In addition, patients with a normal appendix removed had a significantly longer length of stay and higher total charge for the admission, case fatality rate, and rate of infectious complications ([Flum 2002](#)).
-

Conclusion

- **D**uring the past decade, CT has emerged as the dominant imaging method for evaluation of adults with suspected appendicitis. Many different protocols using differing combinations of oral, rectal, IV and no contrast material have been proposed.
 - **R**egardless of the technique used, the reported accuracy in diagnosing appendicitis is high, in the range of 90-99%. Sensitivity and specificity of CT have also been high, at 87-100% and 83-100%, respectively.
-

-
- Ct is considered to be the initial diagnostic tool of choice for confirming suspected appendicitis in adult patients with a normal or obese body habitus.
 - CT has better sensitivity and specificity than US, but we need to evaluate the value of CT's improved diagnostic performance versus its cost and availability.
 - It is a safe, reliable, and accurate modality for the diagnosis of acute appendicitis, especially in patients with equivocal presentation.
-

Take home message

“No single evaluation can substitute for the diagnostic accuracy of the experienced physician.”

The decision to obtain US or CT scan studies depends on institutional preference and the available user expertise, although patient age, sex, and body habitus are important influencing factors.



References

- Korndorffer JR Jr, Fellingner E, Reed W. SAGES guideline for laparoscopic appendectomy. *Surg Endosc*. 2010 Apr;24(4):757-61. PMID: 19787402.
 - Society of American Gastrointestinal and Endoscopic Surgeons. Guidelines for Diagnostic Laparoscopy. November 2007. Available at <http://www.sages.org/publications/guidelines/guidelines-for-diagnostic-laparoscopy/>. Accessed April 9, 2013,
 - Rosen MP, Ding A, Blake MA, Baker ME, Cash BD, Fidler JL, et al. American College of Radiology Appropriateness Criteria. Right Lower Quadrant Pain -- Suspected Appendicitis. 2010; (assessed October 5, 2011
 - Bakker OJ, Go PM, Puylaert JB, Kazemier G, Heij HA. Guideline on diagnosis and treatment of acute appendicitis: imaging prior to appendectomy is recommended. *Ned Tijdschr Geneesk* 2010;154:A303
 - Kim SY, Lee KH, Kim K, Kim TY, Lee HS, Hwang SS, et al. Acute Appendicitis in Young Adults: Low- versus Standard-Radiation-Dose Contrast -enhanced Abdominal CT for Diagnosis. *Radiology* 2011;260:437-45.
 - Golash V, Willson PD. Early laparoscopy as a routine procedure in the management of acute abdominal pain: a review of 1,320 patients. *Surgical Endoscopy* 2005;19(7):882-5.
 - Strömberg C, Johansson G, Adolfsson A. Acute abdominal pain: diagnostic impact of immediate CT scanning. *World Journal of Surgery* 2007;31(12):1347-57.
-

-
- Caroline P. Daly¹, Richard H. Cohan¹, Isaac R. Francis¹, Elaine M. Caoili¹, James H. Ellis¹ and Bin Nan. Incidence of Acute Appendicitis in Patients with Equivocal CT Findings *American Journal of Roentgenology*. 2005;184: 1813-1820.
 - Pickhardt PJ, Lawrence EM, Pooler BD, Bruce RJ. Diagnostic performance of multidetector computed tomography for suspected acute appendicitis. *Ann Intern Med*. Jun 21 2011;154(12):789-96
 - Paulson EK, Kalady MF, Pappas TN. Clinical practice. Suspected appendicitis. *N Engl J Med*. 2003 Jan 16;348(3):236-42
 - Parks NA, Schroepfel TJ. Update on imaging for acute appendicitis. *Surg Clin North Am*. 2011 Feb;91(9):141-54. PMID: 21184905.
 - Wolfe J, Henneman P. Acute Appendicitis. In: Marx J, Hockberger R, Walls R, eds. *Rosen's Emergency Medicine*; 2010:1193-9
 - A.A. Mohamed, N.A. Bhat: Acute Appendicitis Dilemma of Diagnosis and Management. *The Internet Journal of Surgery*. 2010 Volume 23.
 - Flum DR, Morris A, Koepsell T, Dellinger EP: Has misdiagnosis of appendicitis decreased over time? *JAMA*; 2001; 286:1748-1753
-